

Case report

UDK 619:636.8

OCCURRENCE OF *THELAZIA CALLIPAEDA* IN CATS - CASE REPORT

Doroteja Marčić¹, Ivan Pavlović²,

Jasna Prodanov-Radulović¹, Igor Stojanov¹, Ivan Pušić¹

¹Scientific Veterinary Institute "Novi Sad", Novi Sad, Serbia

²Institute of Veterinary Medicine of Serbia, Belgrade, Serbia

Abstract

Thelazia callipaeda is a vector-borne zoonotic nematode, a parasite of the conjunctival sac in domestic and wild carnivores (dogs, cats, foxes and wolves) as well as in humans. Over the last decade, the infection with that particular Spirurida in dogs and cats has increased in many European countries, including the Balkans. During the last few years, the infection with this parasite in dogs and foxes has also been detected in Serbia. The first cases of cat infection were detected during 2015 in Belgrade and later in other parts of Serbia. In this paper we present a case report of cat infection with *T. callipaeda*. Adult nematodes were retrieved from the conjunctival sacs of cats during control at the local veterinary ambulance. In total, we extracted 17 adult worms, 11 females and 6 males.

Key words: cats, Serbia, *Thelazia callipaeda*

¹ Corresponding author: dora@niv.ns.ac.rs

POJAVA THELAZIA CALLIPAEDA KOD MAČAKA – PRIKAZ SLUČAJA

Doroteja Marčić¹, Ivan Pavlović²,

Jasna Prodanov-Radulović¹, Igor Stojanov¹, Ivan Pušić¹

¹Naučni institut za veterinarstvo “Novi Sad”, Novi Sad, Republika Srbija

²Naučni institut za veterinarstvo Srbije, Beograd, Republika Srbija

Kratak sadržaj

Thelazia callipaeda je vektorski prenosiva zoonotska nematoda, koja parazitira u konjunktivalnoj kesi domaćih i divljih mesojeda (psi, mačke, lisice i vukovi) i ljudi. Tokom poslednje decenije, infekcija sa tim spiruridama sve češće se javlja kod pasa i mačaka u brojnim evropskim zemljama, uključujući i područje Balkana. U poslednjih nekoliko godina, u Srbiji je takođe ustanovljena infekcija sa ovim parazitima kod pasa i lisica. Prvi slučajevi infekcije kod mačaka su ustanovljeni tokom 2015. godine u Beogradu, a kasnije i u drugim delovima zemlje. U ovom radu predstavljamo prikaz slučaja infekcije *T.callipeda* kod mačke. Odrasle nematode su izvađene iz konjunktivalnih kesa mačaka tokom kontrole u lokalnoj veterinarskoj ambulanti. Ukupno smo izvadili 17 odraslih crva, 11 ženki i 6 mužjaka.

Ključne reči: mačke, Srbija, *Thelazia callipaeda*

INTRODUCTION

Thelazia callipaeda (Spirurida, Thelaziidae), is a nematode parasite attacking the conjunctival sac of domestic and wild carnivores and humans (Anderson, 2000; Otranto et al, 2005; Rossi et al, 1989). The infection is caused by an adult and larval stages of parasites. Parasites are also known as the “oriental eyeworm”, due to the fact that it prevalently occurs in the Far East and in the countries of the former Soviet Union (Khabarovsk Krai) (Otranto et al., 2004). The presence of the worms in the infected hosts may induce clinical signs of various severity, ranging from mild (e.g., conjunctivitis, epiphora and ocular discharge) to severe (e.g. keratitis, corneal ulcers and blindness).

In Europe, the first autochthonous infection was reported in Italy in 1989 (Lia et al., 2000; Rossi et al., 1989). During the past few decades thelaziosis

spread from northern Italy to numerous European countries (e.g. France, Germany, Switzerland, Spain, Portugal) including the Balkan countries (Croatia, Romania, Bosnia and Herzegovina) (Dorchies et al., 2007; Hodžić et al., 2014; Malacrida et al., 2008; Miró et al., 2011; Otranto et al., 2003; Rodrigues et al., 2012). The infection was detected in dogs, cats, foxes and brown hares. Human ocular infections caused by *T. callipaeda* were detected in endemic areas of Italy, France and Spain (Otranto et al., 2008; Otranto et al., 2013).

The first autochthonous cases of infection by *T. callipaeda* in Serbia in dogs were detected in 2012 and in foxes in 2015 (Gajić et al., 2014; Pavlović et al., 2016). The parasites were, in most cases, encountered in animals of the Canidae family, and also in cats (family Felidae) (Maia et al., 2014; Motta et al., 2014; Soares et al., 2013). For that reason, we present a clinical case of thelaziosis in cats.

MATERIAL AND METHODS

In 2016, we observed ocular changes in the left eye of a one year old female cat – mildly increased lacrimation, exudative conjunctivitis and epiphora. The patient is very territorial half-breed, uncastrated three year old domestic male cat. *T. calliapdea* was diagnosed during the treatment after the fight with the other cat. There are other cats and dogs in the patient's habitat, but none of the pet's owners has reported changes of the animal's health status. During observation we established the presence of worms in conjunctival sac. Mechanical removal of worms was performed by washing the eye with sterile 98 physiological saline solution (NaCl 0.9%) recovering a total of seventeen worms. The collected nematodes were preserved in 70% ethanol solution and sent to the laboratory of parasitology of NIVS, Belgrade. For the purpose of further examination, parasites were cleared in lactophenol and nematodes were identified by its morphometric characteristics described by Skrjabin et al. (Skrjabin et al., 1967). We measured the body length and the maximal width of adult parasites, the number and the position of postcloacal papillae and the spicule length in males, as well as the position of the vulva in females.

RESULTS AND DISCUSSION

During our examination we collected 17 samples of adult *T. callipaeda* - 11 females and 6 males. All parasites were located in the left eye of the cat. Male worms ranged from 10.17-13.26 mm in length, and 327-432 µm in width. Female worms ranged from 14.31-17.39 mm in length, and 399-423 µm in width. All

male worms had five pairs of postcloacal papillae on the ventral side of the body. The distance from the position of the cloaca to the end of the tail ranged from 69-81 μm . Right spicule was shorter and its length ranged from 141-150 μm . Left spicule was much longer, ranging from 1.433-1.757 mm. In female worms, vulva was situated anterior to the oesophago-intestinal junction, and the distance between the vulva and buccal extremity ranged from 557-639 μm in length.

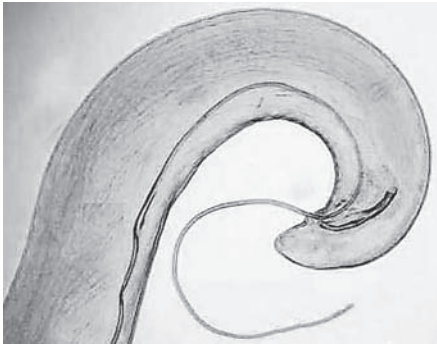

Figure 1.
Caudal end *Thelazia* male

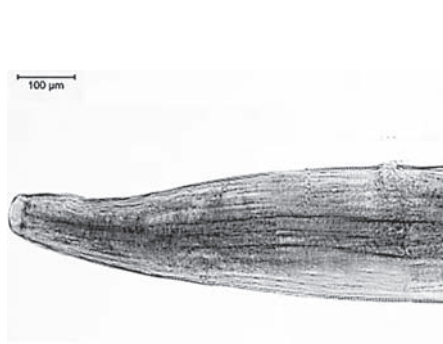


Figure 2.
Thelazia buccal end

Thelazia callipaeda (Spirurida, Thelaziidae) is an arthropod-borne disease. The expansion of this nematode is related to the occurrence of its vector, non-biting dipteran insect – fruit fly *Phortica variegata* (Drosophilidae, Steganiinae). Adult female worms produce first-stage larvae that are ingested by the *P. variegata* that feeds on the lacrimal secretions of the vertebrate hosts (Otranto et al., 2006). It has been noticed that the disease occurs seasonally and primarily in rural areas, where there is a close contact between vector and domestic animals. While still in a vector, larvae develops into the infectious third - stage larvae, which takes 14-21 days and as such larvae may be transferred to the host where they develop into the adult form in the eye cavity during the period of 35 days. The parasite usually lives under the conjunctiva, where the adult females release first stage larvae into the lacrimal secretion (Otranto et al., 2005a; Otranto et al., 2005b). An increased number of cases of infection is usually reported in spring and summer, when the vector is active. Adult parasites remain viable for more than one year, which is crucial for the dynamics pattern of their parasitic abilities, consisting of two peaks of infection: one in the early summer (adult parasites that overwinter) and other in the late summer (adults developing from infectious stages laid by the vector in the early summer) (Otranto et al., 2003; Otranto et al., 2004).

Primary treatment for thelaziosis includes mechanical removal of worms. Additionally, it is recommended to treat infected animals with a macrocyclic lactone (e.g. moxidectin, milbemycin oxime), considering the fact that it can never be guaranteed that the mechanical removal of the worms was entirely successful (Bianciardi et al., 2005).

REFERENCE

1. Anderson R.C.: *Nematode Parasites of Vertebrates: Their Development and Transmission*. Guilford, CABI Publishing, 2000.
2. Bianciardi P, Otranto D.: Treatment of dog thelaziosis caused by *Thelazia callipaeda* (Spirurida, Thelaziidae) using a topical formulation of imidacloprid 10% and moxidectin 2.5%. *Vet. Parasitol.*, 129, 1-2, 89-93, 2005.
3. Dorchies P, Chaudieu G., Siméon L.A., Cazalot G., Cantacessi C., Otranto D.: First reports of autochthonous eyeworm infection by *Thelazia callipaeda* (Spirurida, Thelaziidae) in dogs and cat from France. *Vet Parasitol.*, **149**, 294-297, 2007.
4. Gajić B., Bogunović D., Stevanović J., Kulišić Z., Simeunović P., Stanimirović Z.: Canine and feline thelaziosis caused by *Thelazia callipaeda* in Serbia. *Acta Veterinaria*, 64, 4, 447-455, 2014.
5. Hodžić A., Latrofa M.S., Annoscia G., Alić A., Beck R., Lia R.P., Dantas-Torres F., Otranto D.: The spread of zoonotic *Thelazia callipaeda* in the Balkan area. *Parasit Vectors*, 7, 352, 2014
6. Lia R.P., Garaguso M., Otranto D., Puccini V.: First report of *Thelazia callipaeda* in Southern Italy, Basilicata region. *Acta Parasitology*, 45, 178, 2000.
7. Maia C., Catarino A.L., Almeida B., Ramos C., Campino L., Cardoso L.: Emergence of *Thelazia callipaeda* Infection in Dogs and Cats from East-Central Portugal. *Transboundary and Emerging Diseases*, 63, 4, 416-421, 2014.
8. Malacrida F., Hegglin D., Bacciarini L., Otranto D., Nägeli F., Nägeli C., Bernasconi C., Scheu U., Balli A., Marengo M., Togni L., Deplazes P., Schnyder M.: Emergence of canine ocular thelaziosis caused by *Thelazia callipaeda* in southern Switzerland. *Vet Parasitol.*, **157**, 321-327, 2008.
9. Miró G., Montoya A., Hernández L., Dado D., Vázquez M.V., Benito M., Villagrana M., Brianti E., Otranto D.: *Thelazia callipaeda*: infection in dogs: a new parasite for Spain. *Parasit Vectors*, **4**, 148, 2011.
10. Motta B., Nägeli F., Nägeli C., Solari-Basano F., Schiessl B., Deplazes P., Schnyder M.: Epidemiology of the eye worm *Thelazia callipaeda* in cats from southern Switzerland. *Vet Parasitol.*, 203, 3-4, 287-293, 2014.
11. Otranto D., Ferroglio E., Lia R.P., Traversa D., Rossi L.: Current status and

- epidemiological observation of *Thelazia callipaeda* (Spirurida, Thelaziidae) in dogs, cats and foxes in Italy: a “coincidence” or a parasitic disease of the Old Continent? *Vet Parasitol.*, 116, 315-325, 2003.
12. Otranto D., Lia R.P., Buono V., Traversa D., Giangaspero A.: Biology of *Thelazia callipaeda* (Spirurida, Thelaziidae) eyeworms in naturally infected definitive host. *Parasitology*, 129, 627–633, 2004.
 13. Otranto D., Traversa D.: *Thelazia* eyeworm: An original endo and ectoparasitic nematode. *Trends Parasitol.*, 1, 1–4, 2005a.
 14. Otranto D., Lia R.P., Cantacessi C., Testini G., Troccoli A., Shen J.L., Wang Z.X.: Nematode biology and larval development of *Thelazia callipaeda* (Spirurida, Thelaziidae) in the drosophilid intermediate host in Europe and China. *Parasitology*, 131, 847-855, 2005b.
 15. Otranto D., Cantacessi C., Testini G., Lia R.P.: *Phortica variegata* as an intermediate host of *Thelazia callipaeda* under natural conditions: evidence for pathogen transmission by a male arthropod vector. *Int J Parasitol*, 36, 1167-1173, 2006.
 16. Otranto D., Dutto M.: Human thelaziosis, Europe. *Emerg Infect Dis*, 14, 647-649, 2008
 17. Otranto D., Dantas-Torres F., Brianti E., Traversa D., Petrić D., Genchi C., Capelli G.: Vector-borne helminths of dogs and humans in Europe. *Parasit Vectors*, 6, 16, 2013.
 18. Pavlovic I., Jakić-Dimić D., Kureljušić B., Ćirović D., Jezdimirović N., Drobnjak M.: First occurrence of *Thelazia callipaeda* in foxes (*Vulpes vulpes* L.) in Serbia. *Balkan J Wildl Res*, 3, 2, 2016.
 19. Rodrigues F.T., Cardoso L., Coutinho T., Otranto D., Diz-Lopes D.: Ocular thelaziosis due to *Thelazia callipaeda* in a cat from northeastern Portugal. *J Feline Med Surg.*, 14, 952-954, 2012.
 20. Rossi L., Bertaglia P.: Presence of *Thelazia callipaeda* Railliet and Henry, 1910, in Piedmont, Italy. *Parassitologia*, 31, 167-172, 1989.
 21. Skrjabin K.I., Sobolev A.A., Ivashkin V.M.: Spirurata of animals and man and the disease caused by them. Part 4: Thelazioidea. In: Essential of Nematodology. Vol. XVI. Moscow, USSR: Academy of Sciences of the USSR, 1967.
 22. Soares C., Sousa S.R., Anastacio S., Matias M.G., Marques I., Mascarenhas S., Vieira M.J., Carvalho L.M., Otranto D., Feline thelaziosis caused by *Thelazia callipaeda* in Portugal. *Vet Parasitol.*, 196, 528-531, 2013.

Primljeno: 20.11.2016.

Odobreno: 15.12.2016.