

## MONITORING OF POSTOPERATIVE COURSE AFTER STERILIZATION IN CATS OF DIFFERENT REPRODUCTIVE STATUS AFTER THE USE OF XYLASINE/KETAMINE ANESTHESIA

Milena Samojlović<sup>1</sup>, Ivana Davidov<sup>2</sup>, Jelena  
Apić<sup>1</sup>, Biljana Božić<sup>1</sup>, Ivan Stančić<sup>2</sup>

<sup>1</sup>Scientific Veterinary Institute „Novi Sad“, Novi Sad, Serbia

<sup>2</sup>Faculty of Agriculture, Novi Sad, Serbia

### Abstract

Surgical sterilization (ovariohysterectomy) is one of the most common surgical procedures in small veterinary practice because it represents the safest way to control the population of cats. The aim of this study is to compare postoperative recovery in three groups of cats (estrous, anestrous and gravid cats) after performed ovariohysterectomy using combination of xylasine/ketamine anesthesia and, on the basis of obtained data, determine whether there are some significant differences in postoperative recovery in these three groups of cats. This study included 45 cats that were divided into three groups. First group consisted of 15 cats in estrous, second group consisted of 15 cats in anestrous and the third group consisted of 15 gravid cats. Ovariohysterectomy was performed in private veterinary clinic. Anesthetic protocol was the same for all cats, that is, combination of xylasine and ketamine at appropriate doses according to body weight. Parameters that were followed through postoperative course were appetite, body temperature, appearance of the wound and activity. Data was collected on the first and third day after surgery. Analysis of the collected data shows relatively uniform results among groups of cats considering all followed parameters. Results in this study did not show any significant differences in response to xylasine/ketamine anesthesia among cats of different reproductive status through monitoring of postoperative course.

**Key words:** anesthesia, cats, postoperative course, reproductive status

## MONITORING POSTOPERATIVNOG TOKA NAKON STERILIZACIJE MAČAKA RAZLIČITOG REPRODUKTIVNOG STATUSA PRIMENOM KSILAZIN/KETAMIN ANESTEZIJE

Milena Samojlović<sup>1</sup>, Ivana Davidov<sup>2</sup>, Jelena  
Apić<sup>1</sup>, Biljana Božić<sup>1</sup>, Ivan Stančić<sup>2</sup>

<sup>1</sup>Naučni institut za veterinarstvo „Novi Sad“, Novi Sad, Srbija

<sup>2</sup>Poljoprivredni fakultet, Novi Sad, Srbija

### Kratak sadržaj

Hirurška sterilizacija (ovariohisterektomija) je jedna od najčešće izvođenih hirurških procedura u maloj praksi zato što predstavlja najsigurniji način kontrole populacije mačaka. Cilj ovog rada bio je da uporedi tok postoperativnog oporavka kod tri grupe mačaka (estrične, anestrične i gravidne mačke) nakon izvršene sterilizacije primenom kombinacije ksilazin/ketamin anestezije i da se na osnovu prikupljenih podataka utvrdi postoje li značajne razlike u postoperativnom oporavku kod ove tri grupe mačaka. Ovo istraživanje obuhvatilo je 45 mačaka podeljenih u tri grupe. Prva grupa obuhvatila je 15 mačaka u estrusu, druga grupa 15 mačaka u anestrusu i treća grupa 15 gravidnih mačaka. Sterilizacija je izvršena u privatnoj veterinarskoj ambulanti. Anestetički protokol je bio isti za sve mačke, kombinacija ksilazina i ketamina u odgovarajućim dozama spram telesne mase životinje. Parametri praćeni tokom postoperativnog toka bili su apetit, telesna temperatura, izgled rane i aktivnost. Podaci su prikupljeni prvog i trećeg dana postoperativno. Analiza prikupljenih podataka pokazuje relativno ujednačene rezultate između tri grupe mačaka posmatrano za sve praćene parametre. Tokom monitoringa postoperativnog toka rezultati u ovom radu nisu pokazali značajne razlike u odgovoru na primenu ksilazin/ketamin anestezije među mečkama različitog reproduktivnog statusa.

**Ključne reči:** anestezija, mačke, postoperativni tok, reproduktivni status

### INTRODUCTION

Surgical sterilization (ovariohysterectomy) is one of the most common surgical procedures in small veterinary practice because it represents the safest way to control the population of cats (*Stančić I. et al, 2015*). The importance of cat population control is shown in a study (*Animal Shelter Reporting Study*)

that reported that some 4 to 9.5 million cats are euthanized annually in USA (Kirpensteijn J., 2008). A TNR (trap-neuter-return) program for stray animal population control has been first developed in Europe during 1970s, and later in the USA. Through this program, stray animals are humanly trapped, sterilized and medically treated and then returned to the locations where they were found. Because of the lack of information about these animals and inability to catch them again, many cats are sterilized during lactation, estrous and pregnancy. Besides the cat population control, other benefits of sterilization include prevention of diseases and tumors of reproductive organs.

Surgical complication rates associated with ovariohysterectomy in healthy dogs and cats have been reported to range from 6.2% to 20.6%, depending on surgeon experience. The majority of complications is mild and generally consists of incisional inflammation or gastrointestinal tract upset. Incision complications are more common in larger animals and animals with longer surgery and anesthesia times (De Tora M., McCarthy J., 2011). Problems associated with incisional healing are some of the most frequently reported complications following OVH surgery. It is interesting to note that the incidence of incisional swelling, wound infection, and abdominal dehiscence has not decreased over the past 40 years (Adin C., 2011). Wide range of complications is due to different definition of complications in different studies. Most frequent complications are mild and require only care of the owner and no veterinary intervention. The incidence of complications is lower in younger animals, where one study identified fewer complications in animals in puberty, and other 2 years of age as limit for handling sterilization without complications (Flaggella and Aronsohn, 1994; Pollari et al., 1996; Howe L.M., 1997; Romagnoli S., 2008). In a study, which included 98 puppies and 98 kittens brought to sterilization, complications due to anesthesia were 0% in both groups (Flaggella and Aronsohn, 1993, 1994).

In surgical practice, it is sometimes impossible to predict the duration of surgery. A number of complications that can occur during surgery can prolong duration of the procedure for even up to several hours. It is not uncommon that due to disorder of homeostatic mechanisms, recovery from anesthesia can take many hours (Spasojević Kosić Lj., Trailović D., 2011). Anesthesia of feral cats presents unique challenges. Feral cats are usually of unknown age, history, body weight, and health status. Depending on the situation, they may be malnourished, ill, or heavily parasitized. The wild temperament of feral cats prevents examination prior to chemical immobilization and increases the stress associated with trapping and transportation. The ideal anesthetic agent for feral cats would be delivered in a small volume, induce rapid immobili-

zation, provide a surgical plane of anesthesia, have a predictable and sufficient duration of effect, have a rapid recovery, provide adequate postoperative analgesia, and have a wide margin of safety. Xylazine is a mixed  $\alpha_1$ - and  $\alpha_2$ -adrenergic receptor agonist. Xylazine contributes short duration analgesia, sedation, and muscle relaxation (Cistola A.M. et al., 2004). The analgesic effects of xylazine are not dose dependent, lasting only 20 minutes even when xylazine is administered in high doses. The effects of xylazine can be reversed with a  $\alpha_2$ -adrenergic receptor antagonist such as yohimbine. Because of the short analgesic effects of xylazine, yohimbine reverses the residual sedative effects produced by xylazine (Williams L.S. et al., 2002). Ketamine hydrochloride is classified as a short-acting dissociative anesthetic that is used for chemical restraint, anesthesia induction, and surgical anesthesia in cats (Saywer et al. 1993). It is a rapid-acting general anesthetic that has significant analgesic activity and lacks cardiopulmonary depressant effects (Plumb, 2005). In the past, ketamine has been recommended for most surgical procedures in cats, including abdominal surgery (Evans et al., 1972). Lack of complete muscular relaxation makes ketamine unsuitable as a sole anesthetic agent (Bill, 2006). Recommended doses vary depending on desired depth of anesthesia, route of administration, and the use of other anesthetics concomitantly. In cats, ketamine can be given in doses ranging from 2-33 mg/kg, although doses of 50 mg/kg have been used without fatalities (Arnbjerg, 1979; Wright, 1982). Duration of anesthesia is approximately 30 to 45 minutes (Lumb and Jones, 1973). Ketamine offers many advantages. The route of administration is versatile as it can be administered subcutaneously, intravenously, intramuscularly, orally, and rectally (Wright, 1982; Hanna et al., 1988; Wetzel and Ramsay, 1998).

Considering the facts that many cats are sterilized during estrous or pregnancy, either because of TNR program or the lack of knowledge of their owners, we created this study to monitor postoperative course in cats of different reproductive status during several days after sterilization. The aim of this study is to compare postoperative recovery in three groups of cats (estrous, anestrous and gravid cats) after preformed ovariohysterectomy using combination of xylazine/ketamine anesthesia and on the basis of obtained data determine whether there are some significant differences in postoperative recovery in these three groups of cats.

## MATERIAL AND METHODS

This study included 45 cats that were divided into three groups according to the appearance of their uterus in situ during surgery. First group consisted

of 15 cats in estrous, second group consisted of 15 cats in anestrus and the third group consisted of 15 gravid cats. Ovariohysterectomy was performed in private veterinary clinic. Preoperative procedure included clinical examination and withholding of food and water. The technique of sterilization used in these cats was through ventral midline with removal of the uterus and ovaries. Anesthetic protocol included premedication with xylazine (*Xylased<sup>®</sup>*) at a dose of 2mg/kg i/m., and 15 minutes later intramuscular application of ketamine (*Ketamidor<sup>®</sup>*) at a dose of 10 mg/kg. Parameters that were followed through postoperative course were appetite, body temperature, appearance of the wound and activity. Abdominal wall was closed in two layers, peritoneum and muscles with simple continuous pattern and the skin with simple interrupted pattern with use of absorbable suture (*Vicryl 3-0*). On the first and third day after surgery, all cats were brought to clinic for postoperative therapies – amoxicillin (*Clamoxyl LA<sup>®</sup>*) at a dose of 15 mg/kg.

## RESULTS AND DISCUSSION

Analysis of the data collected on first and second postoperative day is shown in percentages. On the first day post surgery, 33.33% of gravid, 33.33% of estrous and 40% of anestrus cats did not consume any amount of food. On the third day post surgery, the results revealed that all anestrus cats had appetite while 6.67% of gravid and 6.67% of estrous cats had no appetite at all (Fig 1).

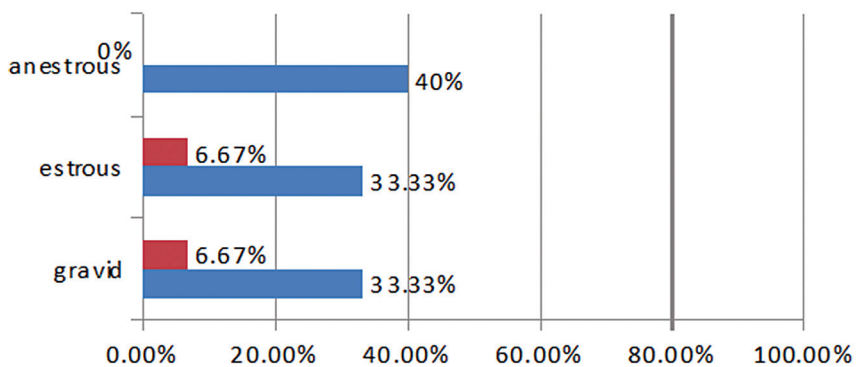


Fig 1. Lack of appetite

13.33% of gravid, 66.67% of estrous and 26.67% of anestrus cats had fever (body temperature higher than 39.2 °C) on the first day post surgery. Situation on the third day was more uniform as it can be seen in Fig 2, where 46.67% (7) of gravid, 40% of estrous and 33.33% of anestrus cats had fever.

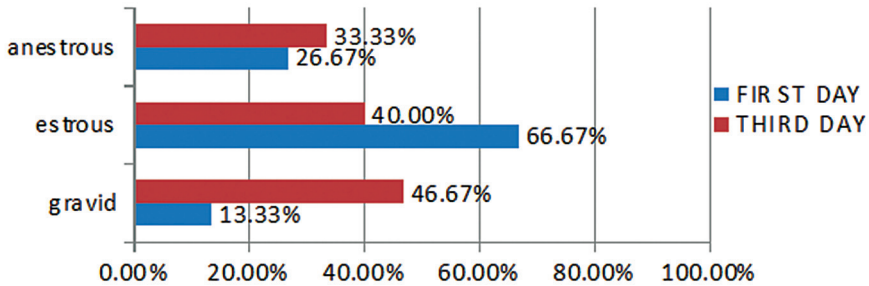


Fig 2. Body temperature above 39,2 °C

On the first day postoperatively, the highest activity rate was observed among anestrus cats, where 80% of cats were active. 66.67% of estrous cats showed activity and only 53.33% of gravid cats showed activity on the first day. All estrous cats were active on the third day, while 93.33% of gravid and anestrus cats showed activity on that day (Fig 3).

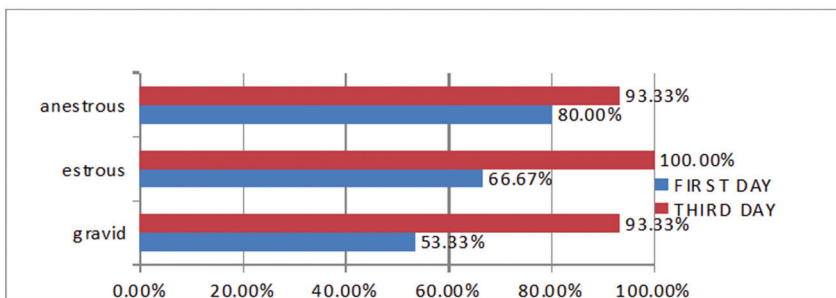


Fig 3. Activity

Monitoring of wound healing showed following results. On the first day postoperatively, 93.33% of all cats presented with proper wound and only

6.67% of cats had dry wound with mild swelling at the incision site. On the third day postoperatively, proper and dry swollen wounds were observed in 44.45% and 42.22% of cats, respectively, whereas 13.33% of cats manifested wound that was inflamed, swollen and with presence of discharge. Comparative analysis among three groups of cats revealed mostly uniform results, where on the first postoperative day 86.67% of gravid, 100% of estrous and 93.33% of anestrus cats had proper wounds. On the third day postoperatively, proper wounds were seen in 46.67% of gravid, 46.67% of estrous and 40% of anestrus cats (Fig 4).

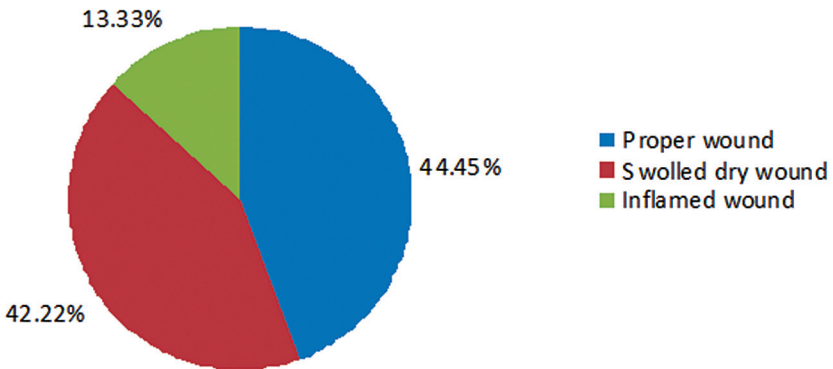


Fig 4. Appearance of the wound on third day postoperatively

Perioperative mortality is extremely low in feral cats anesthetized with TKX-tiletamine/xylazine/ ketamine combination (0.3%). In a study that included 4427 sterilized cats, total mortality rate of 0.35% was found, and the mortality rate suspected to be attributable solely to anesthesia was 0.23% (*Williams et al., 2002*). In our study, none of the cats died due to complications of any kind after surgery. It can be assumed that female cats, undergoing a more invasive surgery than males, do not receive adequate duration of postoperative analgesia from a single dose of TKX (*Cistola et al., 2004*). This can be the reason why cats showed increased attention to surgical wound as the days went by. Complications of surgical incision site are most frequent complications after sterilization and can range from 1% to 4%. Other complications can include dehiscence, wound abscesses, anorexia, lethargy and slow recovery (*Pollari, Bonnet, 1996*). Complications as anorexia, lethargy and inflammation of incision site are all seen in our study. Distribution of these complications among three groups of cats of different reproductive status is very uniform

and shows no significant differences among groups. According to experience of veterinary surgeon, cats and dogs that are pregnant or in heat can be safely sterilized despite those conditions (Appel 2001, Looney et al., 2008). Results obtained in our study did not show any differences in response to xylazine/ketamine anesthesia among cats of different reproductive status.

## CONCLUSION

On the basis of the obtained results, we can get following conclusions:

1. Monitoring of postoperative course in cats of different reproductive status revealed no significant differences in response to xylazine/ketamine anesthesia among these three group of cats
2. Postoperative complications after performed sterilization are more dependent on postoperative care and handling than on reproductive status of the cats

## REFERENCES

1. Adin C.: Complications of ovariohysterectomy and orchietomy in companion animals. *Vet Clin Small Anim* 41, 1023-1039, 2011
2. Appel L.: Chapter 22: Spay Neuter. In: Miller L, Zawistowski S. (eds): Shelter Medicine for Veterinarians and Staff. Ames, IA: Blackwell Publishing, 2001
3. Arnbjerg J.: Clinical manifestations of overdose of ketamine-xylazine in the cat. *Nord Vet Med* 31, 155-161, 1979
4. Bill R.: Clinical Pharmacology and Therapeutics for the Veterinary Technician (3rd edn.). Mosby Elsevier, St. Louis, USA, 2006
5. Cistola A.M., Golderb F.J., Centonze L.A., McKaya L.W., Levy J.K. : Anesthetic and physiologic effects of tiletamine, zolazepam, ketamine, and xylazine combination (TKX) in feral cats undergoing surgical sterilization. *Journal of Feline Medicine and Surgery* 6, 297-303, 2004
6. De Tora M., McCarthy R.J.: Ovariohysterectomy versus ovariectomy for elective sterilization of female dogs and cats: is removal of the uterus necessary? *JAVMA*, Vol 239, No. 11, 1409-1412.2011
7. Evans A., Krahwinkel D., Sawyer D.: Dissociative anesthesia in the cat. *Journal of the American Animal Hospital Association* 8, 371-373, 1972
8. Faggella A.M., Aronsohn M.G.: Anesthetic techniques for neutering 6- to 14 -week-old kittens. *J Amer Vet Med Assoc* 202, 56-62, 1993
9. Faggella A.M., Aronsohn M.G.: Evaluation of anesthetic protocols for neutering 6-14-week old pups. *J Amer Vet Med Assoc* 205, 308-314, 1994



10. Hanna R.M., Borchard R.E., Schmidt S.L.: Pharmacokinetics of ketamine HCl and metabolite I in the cat: a comparison of i.v., i.m., and rectal administration. *J Vet Pharmacol Ther* 11, 84-93, 1988
11. Howe L.M.: Short-term results and complications of prepubertal gonadectomy in cats and dogs. *J Amer Vet Med Assoc* 211, 56-62, 1997
12. Kirpensteijn J.: Ovariectomy versus ovariohysterectomy . Is the eternal argument ended? In: Proceedings of the International SCIVAC Congress, Rimini, Italy, 290-293, 2008
13. Looney A.L., Bohling M.W., Bushby P.A. et al.: The Association of Shelter Veterinarians veterinary medical care guidelines for spay/neuter programs. *J Am Vet Med Assoc* 233:74-86, 2008
14. Lumb W.V., Jones E.W.: *Veterinary Anesthesia*. Lea & Febiger, Philadelphia, USA, 1973
15. Pollari F.L., Bonnett BN., Bamsey SC., Meek AH., Allen DG.: Postoperative complications of elective surgery in dogs and cats determined by examining electronic and paper medical records. *J Amer Vet Med Assoc* 208, 1882-1886, 1996
16. Plumb D.C.: *Plumb's Veterinary Drug Handbook* (5th edn.). Blackwell Publishing, Ames, IA, USA, 2006
17. Romagnoli S.: Surgical gonadectomy in the bitch and queen: should it be done and at what age? In: Proceedings, Southern European Veterinary Conference and Congreso Nacional AVEPA, Barcelona Spain, 2008
18. Saywer D, Rech R, Durham R.: Does ketamine provide adequate visceral analgesia when used alone or in combination with acepromazine, diazepam, or butorphanol in cats? *Journal of the American Animal Hospital Association* 29, 257-263, 1993
19. Spasojević Kosić Lj., Trailović D.R.: Kardiovaskularni poremećaji indukovani anestezijom produženom anestezijom kod pasa kod. *Arhiv veterinarske medicine*, 4, 1, 31-45, 2011
20. Stančić I., Dubljević M., Toholj B., Davidov I.: Uticaj reproduktivnog statusa na zarastanje rane kod ovariohisterektomisanih mačaka. U: Zbornik radova, 26. Savetovanje veterinara Srbije, Zlatibor, 181-184 , 2015
21. Wetzell R.W., Ramsay E.C.: Comparison of four regimens for intraoral administration of medication to induce sedation in cats prior to euthanasia. *J Am Vet Med Assoc* 213, 243- 245, 1998
22. Williams, L.S., Levy, J.K., Robertson, S.A., Cistola, A.M., Centonze, L.A.: Use of the anesthetic combination of tiletamine, zolazepam, ketamine, and xylazine for neutering feral cats. *Journal of the American Veterinary Medical Association* 220, 10, 1491-1495, 2002

23. Wright M.: Pharmacologic effects of ketamine and its use in veterinary medicine. *J Am Vet Med Assoc* 180, 1462-1471, 1982

Primljeno: 25.12.2015.

Odobreno: 15.01.2016.