



Adult human case of toxocariasis with pulmonary migratory infiltrate and eosinophilia

Toksokarijaza kod odrasle osobe sa migratornim plućnim infiltratom i eozinofilijom

Djordje Považan*, Mirna Djurić*, Vera Uzurov-Dinić†,
Dušan Lalošević‡, Vesna Lalošević§, Svetozar Sečen†, Anika Považan*

*Institute for Pulmonary Diseases of Vojvodina, Sremska Kamenica, Serbia; †Clinical Center of Vojvodina, Novi Sad, Serbia; ‡Pasteur Institute, Novi Sad, Serbia; §University of Novi Sad, Faculty of Agriculture, Novi Sad, Serbia

Abstract

Introduction. Toxocariasis is a zoonosis which is in Serbia characterized with a very high infection rate of dogs and excessive contamination of the soil with the eggs of *Toxocara canis*, the agent of the disease. *Toxocara*-induced infections have in recent years been established in a few hundreds of children, but toxocariasis has rather rarely been diagnosed in adults. **Case report.** We reported toxocariasis (*visceral larva migrans*) in an adult, manifested by migratory pulmonary infiltrates and positive serological test finding to *Toxocara*. **Conclusion.** Human toxocariasis is a rare disease in adults, therefore it should be considered in adult patients presented with eosinophilia and migratory pulmonary infiltrates.

Key words:

toxocariasis; lung diseases; diagnosis, differential; eosinophilia; fluorescent antibody technique; adult.

Apstrakt

Uvod. Toksokarijaza je zoonoza koja se u Srbiji karakteriše vrlo visokom stopom infekcije pasa i jako kontaminiranim zemljištem jajima parazita *Toxocara canis*, uzročnika bolesti. Poslednjih godina dokazane su infekcije ovim uzročnikom kod više stotina dece, međutim, kod odraslih osoba, toksokarijaza se veoma retko dijagnostikuje. **Prikaz bolesnika.** Prikazali smo toksokarijazu (*visceral larva migrans* – VLM) kod odrasle osobe koja se manifestovala migratornim plućnim infiltratima i pozitivnim serološkim analizama prema *Toxocara canis*. **Zaključak.** Humana toksokarijaza je retko oboljenje kod odraslih osoba, pa na nju treba misliti kod bolesnika sa eozinofilijom i migratornim plućnim infiltratima.

Ključne reči:

toksokarijaza; pluća, bolesti; dijagnoza, diferencijalna; eozinofilija; fluorescentna antitela, tehnika; odrasle osobe.

Introduction

Toxocariasis is a well-known parasitic zoonosis caused by *Toxocara canis*, with the soil transmission cycle which includes dogs and other canis as natural hosts and many mammals and birds as paratenic or transport hosts. Toxocariasis is present in nearly 100% of the dog population in Serbia, due to transplacental infection of puppies and climate conditions suitable for embryonation of *Toxocara ova* in the soil, especially in urban places and children playgrounds^{1,2}. The major route of transmission to humans is through the ingestion of embryonated *ova* from the soil. As in other regions with a temperate climate, in Serbia toxocariasis has been diagnosed mostly in children, as visceral and rarely ocular involvement³⁻⁵. However, in adults

toxocariasis has obscure symptoms and in Serbia it has been extremely rarely confirmed, mostly in its ocular form⁵. Migratory eosinophilic pneumonia induced by the visceral larva migrans in adults is not a common manifestation of toxocariasis, motivating us to report the case of a 20-year the female patient.

Although most human infections are asymptomatic, two well-defined clinical syndromes are classically recognized: *visceral larva migrans* and *ocular larva migrans*. Additional two less severe syndromes have also been described one mostly in children (covert toxocariasis), and the other prevailing in adults (common toxocariasis)⁶⁻⁸. The diagnosis is established on the basis of laboratory findings of excessive eosinophilia, particularly the finding of specific antibodies to *Toxocara* in blood. Exceptionally polymorphic clinical pres-

entation makes the clinical diagnosis of toxocariasis difficult, so the diagnostic algorithm should be strictly applied⁹.

We reported case of an adult toxocariasis with pulmonary involvement, the diagnosis difficult to establish.

Case report

In 2006, a 20-year old female patient was admitted to the Institute for Pulmonary Diseases of Vojvodina (IPDV) in Sremska Kamenica, Serbia, with a few months long history of symptoms, including occasional subfebrile body temperatures, fatigue, hyperhidrosis and bilateral lung lesions seen on chest computerized tomography (CT) finding, accompanied with persisting eosinophilia in the blood. Due to these symptoms, the patient visited the doctor several times and had total blood count analyses. Having performed CT screening of the chest to more accurately enlighten the morphology of lung lesions seen on the chest radiography, the patient was referred to the Institute for Pulmonary Diseases of Vojvodina (IPDV).

On admission, the patient was conscious, oriented, subfebrile, without cardiac disease, with a slightly enlarged lymph node on the left neck, complaining about fatigue and excessive sweating, free of cough or skin lesions. The anamnestic data revealed the patient came from the country and had puppy pets.

The chest radiography finding was presented with an excessively marked bronchovascular contour and a tiny, roundish, inhomogeneous lesions partially in the intermediary and lower lung portions bilaterally and one infiltrate on the left basal field (Figure 1). The CT finding obtained immediately prior to admission was presented with roundish, unclearly delineated to the periphery, inhomogeneous, hyperdense lesions of 6–8 mm in the diameter, localized on the left, in the projection of the basal and the Fowler's segment. The finding suggested micronodular infiltrative lesions were involved in these localizations, and one infiltrate over 1 cm on the left (Figure 1).

and virological tests were negative. The sputum and catheter biopsy samples examined for *Mycobacterium tuberculosis* by smear and by culture were negative. Bacteriological findings of the nose and throat swab samples, as well as the sputum ones were negative, as well. The cytological sputum analysis recurrently suggested the presence of eosinophil granulocytes. The stool assay for parasite eggs and larvae was negative.

Lung function tests were normal, and the bronchial challenge with carbachol was negative, as well. Blood gas analyses at rest and on exertion of 80 W were normal. Allergy examination by a prick test revealed no hypersensitivity to examined standard inhalant allergens.

Ultrasound (US) scanning of the upper abdomen showed the liver approximated 151 mm in diameter, with a homogeneous structure, and the pancreas, spleen and gall bladder were normal, as well.

The bronchoscopy finding was normal, and all the histological samples (catheter biopsy and transbronchial biopsy) taken from the left lung in the course of bronchoscopy had normal features, excluding the presence of few eosinophils. Bronchoalveolar lavage (BAL) of the middle lobe revealed the increased presence of eosinophils (24%), with 64% macrophages, 8% lymphocytes and 4% segmented neutrophils.

To better enlighten discrete lung lesions, a control CT screening of the chest was performed three weeks later, revealing infiltrative migratory lesions of an altered localization and density as compared to those seen in the former CT finding.

Due to enlarged cervical lymph nodes and as recommended by the hematologist, magnetic resonance (MR) imaging of the neck and endocranium was performed, revealing cervical lymphadenomegaly (enlarged nuchal lymph nodes bilaterally with the largest diameter of 12.8 mm, as well as the supraclavicular ones on the right, reaching 11.8 mm in diameter), without pathological lesions in the endocranium.

A high percentage of eosinophils (17%) persisted in blood. Taking into account the age of the patient, laboratory

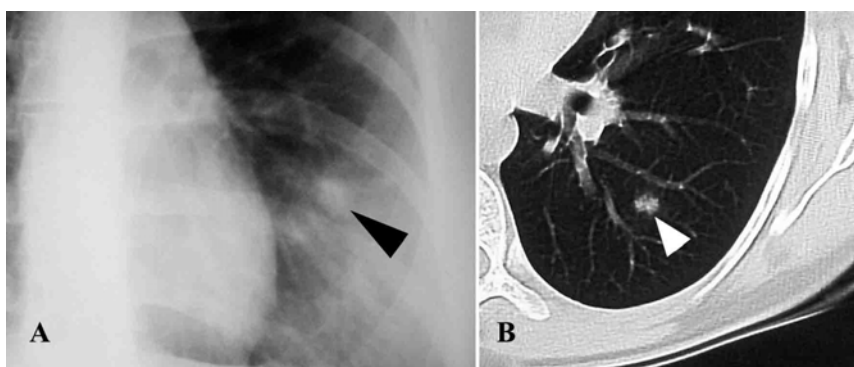


Fig. 1 – A) the patient's chest radiography; B) computerized tomography scan on admission, the largest infiltrate (arrowhead)

The following blood test findings were obtained: erythrocyte sedimentation rate was 20/35, C-reactive protein (CRP) level < 6 mg/L, and white blood count (WBC) $5.3 \times 10^9/L$, with 18% of eosinophils, and immunoglobulin levels of IgA 4.4 g/L, IgM 3.6 g/L, IgG 13.1 g/L. The tuberculin

and chest CT findings, the diagnosis of the hypereosinophilic syndrome and eosinophilic pneumonia was established.

Corticosteroid therapy (prednisone 30 mg per day) was initiated resulting in a complete radiological regression and eosinophil count reduction in ten days. The patient's general

condition was satisfactory, but elevated eosinophil counts in the peripheral blood persisted. After a 6-month corticosteroid treatment, eosinophil count was normalized (5% of eosinophils), so corticosteroids were discontinued. But, as the eosinophil count increased to 28% as soon as the corticosteroid treatment had been discontinued (Figure 2), corticosteroids were reintroduced into the treatment to include daily prontosone doses of 30 mg per day.

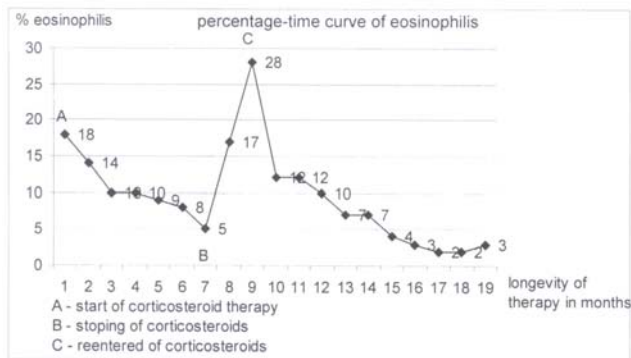


Fig. 2 – Eosinophilia: course and levels with and without corticosteroid therapy

To enlighten the etiology of persisting eosinophilia, additional analyses were performed: antistreptolysin titre, antiechinococcal antibodies, antinuclear, antimitochondrial, antithyroid, antiparietal, anti-smooth muscle and anticardiac antibodies, and they were negative. Complement 3 (C₃) and complement 4 (C₄) findings were normal, too. The ultrasound (US) and hormone findings of the thyroid were normal, as well. The cytological finding of the bone marrow sample was presented with an elevated percentage (15%) of eosinophil cells. The repeat examinations of the stool and perianal print samples revealed no eggs of intestinal parasites. The assay for eosinophils of the nose secretion sample established 300 eosinophils per low magnification microscopic field.

Cytological analysis of the sputum and nose secretion sample, and the histological assay of the transbronchial biopsy sample established the presence of eosinophils, accompanied with an increased percentage of eosinophils in the BAL and bone marrow sample and eosinophilia in blood suggest idiopathic hypereosinophilic syndrome with pulmonary involvement.

At the end, the indirect immunofluorescent test for toxocariasis in the serum was significantly positive, in the titre of 1 : 80 in the course of corticosteroid treatment.

A team of experts including a pulmonologist, hematologist, parasitologist and an immunologist, indicated that the treatment with low-dose prednisolone accompanied with a further follow-up of the patient, should also include an antihelminthic drug (albendazole in the dose of 15 mg/kg/body mass over 30 days), establishing the final diagnosis: Toxocariasis, *Pneumonia eosinophilica*, *Eosinophilia persistens*.

At subsequent controls the patient was free of symptoms, with normal eosinophil count in blood, without patho-

logical lesions in radiography, and the negative finding of the immunofluorescent test for toxocariasis was achieved after two years.

Discussion

Migratory pulmonary infiltrates, eosinophilia in blood and bronchial exudate and positive serology suggested the diagnosis of toxocariasis in our patient. After the hospital treatment and a long-term outpatient treatment and control, a regression of eosinophilia and negative serological assay two years later, strongly confirmed the diagnosis of the classical *larva migrans* syndrome caused by *Toxocara canis*. A long diagnostic procedure in our patient was due to a great rarity of toxocariasis in adult population in Serbia. So far, just a few cases of ocular involvement in adults have been registered⁵, in contrast to a great number of cases in children with diverse clinical manifestations².

The infection of children is easy to explain. The georal transmission, especially in children with geophagia, is well-known. In adult patients without risky behavior, with good hygienic standards, the *Toxocara* infection is possible by ingestion of infected meat of other paratenic hosts. Meat as a source of infection has been mentioned in the literature. Serological investigations in Britain have shown that the pig serves as a paratenic host for *Toxocara canis*, with 4.5% of pigs having antibodies against *Toxocara canis*^{10,11}. Seroepidemiological studies throughout the world have shown the most common prevalence of the general population is 2%–7% in moderate climate, but significantly higher in tropical regions. In spite of numerous studies in this field performed in Serbia, we lack accurate data, but it has been well established that toxocariasis is a rare disease in adulthood⁹.

Parasitic infections may induce pulmonary eosinophilia and pulmonary lesions, so it is necessary to have a good knowledge on inducing agents of pulmonary eosinophilia, its manifestations, diagnostic approach and treatment¹².

Toxocariasis is one of the inducing agents of eosinophilic lung infiltrates. A study carried out in Korea reports 102 patients with pulmonary infiltrates diagnosed by CT screening of the chest who also had a positive serological finding in toxocariasis and blood eosinophilia. On the control chest CT finding, 35% of the patients had migratory infiltrates, and 48% of them were presented with regression of pulmonary lesions¹³. Computerized tomography chest screening provides a better morphological presentation of pulmonary lesions, so we apply this imaging technique as other authors. Our reported patient also had migratory infiltrates seen on the control chest CT finding, as described in this case report. Migratory nodular lesions were also seen on the control CT finding in a 30-year old male patient with eosinophilia and a positive serological finding of *Toxocara canis*¹⁴.

The relevance of an elevated percentage of eosinophils in the BAL fluid has also been recognized by the authors from Osaka, who reported a 38-year old female patient with the symptoms of cough, blood eosinophilia, lung infiltrates and 94% of eosinophils in the BAL fluid, while we found 24%. The diagnosis of visceral *larva migrans* (VLM) was

made on the basis of the positive results in the enzyme-linked immunosorbent assay for *Toxocara canis*, supported by the clinical symptoms and laboratory findings¹⁵.

The relevance of chest CT screening and BAL analysis has also been recognized by Polish authors who reported a 32-year old patient with *Toxocara* infection. The diagnosis was confirmed by serological tests with anti-*Toxocara canis* antibodies, bronchial lavage and chest CT scan with disseminated lung lesions¹⁶.

Toxocariasis is one of the inducing agents of eosinophilia in the peripheral blood and eosinophilic infiltrates in an organism. The authors from Israel report that many cases may be diagnosed just as hypereosinophilia syndrome in case the serological test with *Toxocara* is not applied¹⁷. It was the case in our patient who, despite the applied corticosteroid treatment developed an increase and persistence of eosinophils, indicating a larger-scale investigations including an immunofluorescent assay which confirmed toxocariasis. There is no doubt it is crucial to establish an accurate diagnosis, requiring a good knowledge of diagnostic algorithm for eosinophilia. Due to an activated immunoinflammatory reaction, our patient developed enlarged lymph nodes of the neck.

The diagnosis of larval migrans is usually done by immunodiagnostic methods¹⁸.

Serological tests with *Toxocara* are recommended in patients with pulmonary infiltrates of unknown etiology¹³, and the diagnosis of VLM is established by positive serological findings for *Toxocara canis*, together with the clinical symptoms and laboratory findings¹⁴⁻¹⁶.

Having obtained a significantly positive indirect immunofluorescent test finding of toxocariasis in serum in our patient, we introduced albendazole in the treatment. The authors from Osaka reported an adult patient with VLM and pulmonary infiltrates, with histologically established eosinophilic pneumonia persisting for seven weeks prior to introducing the antihelminthic therapy with albendazole¹⁵, that was also the case in our patient in whom all blood findings did not regain normal levels before albendazole had been applied.

The duration of the treatment with albendazole, which is diversely approached, is also analyzed by the authors who report a 42-year old patient with fever, productive cough, dyspnea, ground glass opacities mainly in the upper and middle lung fields on chest radiography. The symptoms dis-

appeared on antibiotic treatment, but eosinophilia persisted, so the investigations were, as in our case, extended and *Toxocara canis larva migrans* was diagnosed. Four-week albendazole treatment was applied, but as eosinophilia reoccur after one month discontinuation, the treatment was prolonged for additional eight weeks¹⁹.

Numerous studies investigated undesirable side effects of albendazole. Some authors, however, recognize its efficacy without side effects for the treatment of toxocariasis in children²⁰. Jevtić et al.²¹ analyze a long-term treatment with high albendazole doses in patients with cystic echinococcosis, establishing significantly elevated transaminase levels in serum, which in most patients regain to normal in six months. New efficient drugs of this group should therefore be discovered^{21,22}.

The clinical forms are non-specific but frequent and varied (neurological, ophthalmologic, pulmonary, cutaneous and sometimes rheumatological)²³. The following skin manifestations have been described in patients with toxocariasis: chronic urticaria, chronic pruritis and eczema. In many cases, these skin manifestations appear as sole symptoms of the disease, developing after antihelminthic treatment⁷. Ocular toxocariasis is usually a unilateral disease and the authors report a 71-year old female patient with ocular toxocariasis of the left eye and unilaterally deteriorated sight and strabism, pointing out the exposure to pets – dogs and cats, as risk factors for *Toxocara infection*⁸.

Our patient had cervical lymphadenopathy, which was resolved after the applied treatment. It correlates with a case report of a 7-year old boy with toxocariasis reporting that the initial corticosteroid cotreatment succeeded by thiabendazole resulted in a regression of lymphadenopathy and normalization of a total blood and eosinophil count²⁴. It is therefore suggested that infection with *Toxocara canis* should be considered in cases with generalized lymphadenopathy accompanied with fever, hepatosplenomegaly and eosinophilia.

Conclusion

We reported a case of visceral *larva migrans* in an adult patient with migratory pulmonary infiltrates and positive serology. Due to a prolonged diagnostic management of our patient, we emphasize this little known zoonosis in adult patients which should be considered in case of eosinophilia and pulmonary infiltrates.

R E F E R E N C E S

1. Kulišić Z, Pavlović I, Milutinović MJ, Aleksić-Bakrač N. Intestinal parasites of dogs and role of dogs in epidemiology of larva migrans in the Belgrade area. *Helminthologia* 1998; 35(2): 79–82.
2. Lalosević D, Gebauer E, Malenković M. The role of toxocariasis in the etiology of hypereosinophilic syndrome in children. *Med Pregl* 1993; 46(11–12): 434–7. (Croatian)
3. Lalosević D, Oros A, Lalosević V, Knezević K, Knezević S, Božić K, et al. Manifestations of visceral and ocular symptoms of toxocariasis in a 6-year-old boy. *Med Pregl* 2001; 54(Suppl 1): 51–3. Croatian.
4. Lalosević D, Radulović S, Mićović Z, Misita V. Identification of *Toxocara canis* larvae in ocular granuloma. *Vojnosanit Pregl* 1994; 51(3): 242–4.
5. Stanković-Babić G, Zlatanović G, Djordjević-Jocić J, Kostovska V, Čekić S. Ocular toxocariasis - A case report. *Acta Fac Med Naiss* 2007; 24(3): 121–4.
6. Rubinsky-Elefant G, Hirata CE, Yamamoto JH, Ferreira MU. Human toxocariasis: diagnosis, worldwide seroprevalences and clinical expression of the systemic and ocular forms. *Ann Trop Med Parasitol* 2010; 104(1): 3–23.

7. *Ganignet B, Piarroux R, Aubin F, Millon L, Humbert P.* Cutaneous manifestations of human toxocariasis. *J Am Acad Dermatol* 2008; 59(6): 1031–42.
8. *Stanković-Babić G, Zlatanović G, Dorđević-Jocić J, Kostovska V, Cekić S.* Ocular toxocariasis: a case report. *Acta Fac Med Naiss* 2007; 24(3): 121–4.
9. *Lalošević D, Lalošević V.* Toxocariasis – larva migrans in humans and animals. Belgrade: Zadužbina Andrejević; 2008. p. 1–105.
10. *Hebigh AB, Lind P, Nansen P.* Visceral larva migrans: migratory pattern of *Toxocara canis* in pigs *Int J Parasitol* 1999; 29(4): 559–65.
11. *Stevenson P.* Toxocara and ascaris infection in British pigs: a serological survey. *Vet Rec* 1979; 104(23): 526–8.
12. *Chitkara RK, Krishna G.* Parasitic pulmonary eosinophilia. *Semin Respir Crit Care Med* 2006; 27(2): 171–84.
13. *Yoon YS, Lee CH, Kang YA, Kwon SY, Yoon HI, Lee JH,* et al. Impact of toxocariasis in patients with unexplained patchy pulmonary infiltrate in Korea. *J Korean Med Sci* 2009; 24(1): 40–5.
14. *Hisamatsu Y, Ishii H, Kai N, Amemiya Y, Otani S, Morinaga R,* et al. Case of toxocariasis showing migratory nodular shadows with halos. *Nihon Kokyuki Gakkai Zasshi* 2008; 46(5): 420–4. (Japanese)
15. *Inoue K, Inoue Y, Arai T, Nawa Y, Kashiva Y, Yamamoto S,* et al. Chronic eosinophilic pneumonia due to visceral larva migrans. *Intern Med* 2002; 41(6): 478–82.
16. *Kuziemski K, Jassem E, Mierzejewska E, Goljan J, Slominski JM.* Lung manifestation of visceral larva migration syndrome due to *Toxocara canis* infection. *Pneumonol Alergol Pol* 1999; 67(11–12): 554–7.
17. *Sayar D, Mazilis A, Kassem E, Klein A.* Toxocariasis as a cause of hypereosinophilia. *Harefuah* 2009; 148(1): 14–6, 89. (Hebrew)
18. *Ishiyama S, Ono K, Rai SK, Uga S.* Method for detecting circulating *Toxocara canis* antigen and its application in human serum samples. *Nepal Med Coll J* 2009; 11(1): 9–13.
19. *Takamatsu K, Sumitani M, Nanjyou S, Nishijima M, Syoji S, Takifuji N,* et al. Case of *Toxocara canis* larva migrans cured by additional treatment with albendazole. *Nihon Kokyuki Gakkai Zasshi* 2008; 46(10): 836–41.
20. *Saporito L, Scarlata F, Colomba C, Infurnari L, Giordano S, Titone L.* Human toxocariasis: a report of nine cases. *Acta Paediatr* 2008; 97(9): 1301–2.
21. *Jevtić M, Mikić D, Arsić-Komljenović G, Stanković N, Ristanović E, Sjenčić G,* et al. Adverse effects of long term, continual administration of high doses of albendazole in the treatment of echinococcal disease. *Vojnosanit Pregl* 2008; 65(7): 539–44. (Serbian)
22. *Mikić D, Jevtić M, Arsić-Komljenović G, Ristanović E, Stanković N, Sjenčić G,* et al. Impossibility of the treatment of inoperable liver multicystic echinococcosis due to adverse reactions to antihelminthics. *Vojnosanit Pregl* 2009; 66(10): 833–9. (Serbian)
23. *Degouy A, Menat C, Aubin F, Piarroux R, Woronoff-Lemsi MC, Humbert P.* Toxocariasis. *Presse Med* 2001; 30(39–40 Pt 1): 1933–8.
24. *Szczerpański T, Sońta-Jakimczyk D, Janik-Moszan A, Olejnik I.* Generalized lymphadenopathy as initial presentation of toxocariasis in a seven-year-old boy. *Pediatr Infect Dis J* 1996; 15(8): 717–8.

Received on January 27, 2010.

Revised on May 4, 2010.

Accepted on May 10, 2010.